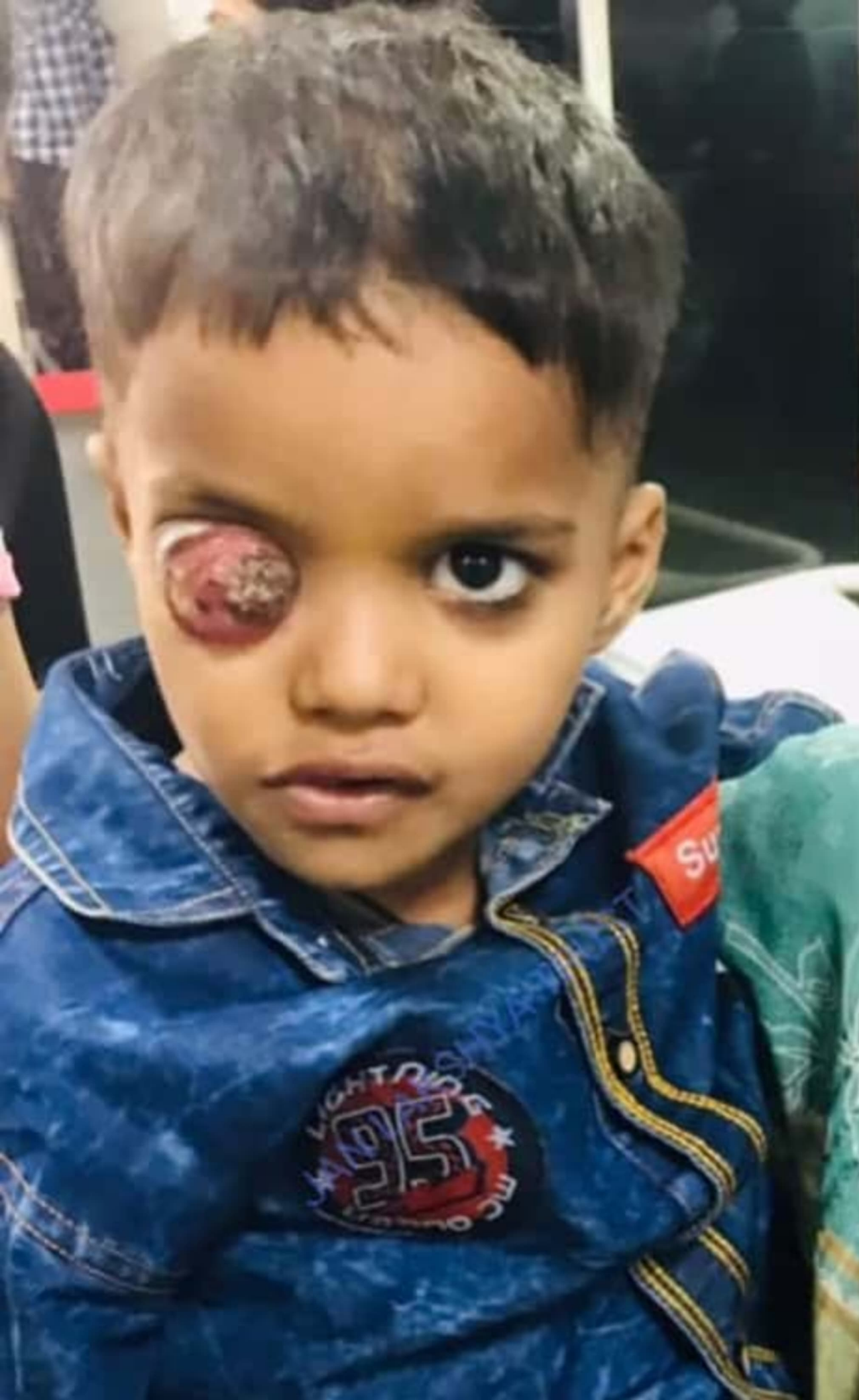



MONITORING AND INVESTIGATIONS CHART PAEDS ER

NAME OF THE PATIENT: Shreya AGE/SEX: 4y / F UHID: 1072766G

VITALS (DATE/TIME)	4/10/24	6PM	3:20			
HR	121	112	102			
RR	24	20	28			
SPO2	98%	100%	100			
BP			92/13			
PERIPHERIES	WARM	WARM	+			
PP/CP	++/++	++/++	++/++			
CRT	2s	2s	2s			
GCS AND PUPILS	E4 V5 M6	E4 V5 M6	10/10			
IONOTROPES	B/L R/L	B/L R/L	B/L			
U.O (ml/kg/hr)						
VITALS (DATE/TIME)						
HR						
RR						
SPO2						
BP						
PERIPHERIES						
PP/CP						
CRT						
GCS AND PUPILS						
IONOTROPES						
U.O (ml/kg/hr)						

JAN LAKSHYATRUST

विकिरण नैदानिक विभाग
अ० भा० आ० सं०, नई दिल्ली-११००२६
DEPARTMENT OF RADIODIAGNOSIS
A.I.I.M.S., NEW DELHI - 110029

PLAIN X-RAY/CONTRAST STUDIES REQUISITION FORM

Name : Anushka. Age/Sex : 44 / F Ref. Dept./Unit : Date : 4/10/24.
Indoor (Bed No.) / Outdoor / Casualty UHID No. : LMP :
Prods 107276663

Examination Required :

Clinical History and Examination :

C/Cx - head → to rule out mets (cvs).

K/ds (R) extraocular RB.
New onset trigem

Clinical / Working Diagnosis :

Blood Urea / S. Creatinine :
Any h / o allergy or asthma :
(for IVU patients only) :

Signature of Referring Physician / Date :

Consent :

I hereby give consent for the performance of any diagnostic or therapeutic radiological procedure with or without the use of contrast injection and / or sedation. The associated complications and risks have been explained to me.

Signature of Patient / Date :

Your appointment is on : _____

Room No. : _____

Time Slot : 8:30 9:00 9:30 10:00 10:30 11:00 11:30 12:00 12:30

X-Ray No. :

Size / No. of Films

Date :

Kvp/mAS:

Sign. of Radiographer :

P.T.O.



Dr. B.R. Ambedkar

Tel
tal

OPD-6

NO. DATE

MR. Name

Age

Sex

Address

Occupation

Referral

Page/ Diagnosis	Date	Treatment
	<p>3/7/24</p> <p>11-7-24</p> <p>4/7/24</p> <p>7:30 AM</p> <p>KC</p>	<p>BL FB OFOB PLUTIVEE MACT</p> <p>उपचार/ Treatment</p> <p>July UCSF 100mgse CO X 5day (निर्देश 15)</p> <p>10PRK - Raycard (Dey. later)</p> <p>Flu vaccination - Report CBC</p> <p>11/7/24 - RFE Renew</p> <p><i>[Signature]</i></p> <p><i>[Stamp]</i></p>

JAN LAKSHYA TRUST

अंगदान-जीवन का बहुमूल्य उपहार / ORGAN DONATION - A GIFT OF LIFE

ORBO AIMS, 26588360, 26593444, www.orbo.org Helpline-1060 (24 hrs. service)

आपके दिल को दान देने के लिए सर्वश्रेष्ठ की सुविधा उपलब्ध है / Dharamshala facility is available for mutilation patients

Flu in old oncology clinic # (142) 2pm
 for Date for (R) emulsion + 1° imples
 ↓ 4A

3 Aug 2024

Ward 1A 8am

JAN LAKSHYA TRUST
 B

नेत्र ईश्वरीय सर्वश्रेष्ठ उपहार है जिनका मनुष्य जीवन में दान करना परमश्रेष्ठ है।
 इनकी पूर्ण रक्षा कीजिए ताकि ये अपनी रक्षा कर सकें।

Eyes are God's most precious gift to man kind and eye donation is the most noble deed.

Take full care of them so that they can take care of you.

ब. रो. वि. कार्ड
O.P.D. Card



अनुभाग व दिन
Section and Day VI
बुधवार व शनिवार
Wednesday & Saturday

कमरा नंबर
Cabin No.

डा. राजेन्द्र प्रसाद नेत्र विज्ञान केन्द्र
अ. भा. आयु. सं., नई दिल्ली-110029

Dr. Rajendra Prasad Centre for Ophthalmic Sciences
A.I.I.M.S., New Delhi-110029

यू.एच.आई.डी. संख्या
UHID No. 1072

आचार्य राधिका टंडन का एकक
Prof. Radhika Tandon's Unit

रोगी का नाम Name of the Patient	पुत्र/पुत्री/पत्नी S/D/W	लिंग Sex	आयु Age	पता Address
ANUSHKA				

दिनांक DATE	निदान DIAGNOSIS
----------------	--------------------

22/7/24

उपचार Treatment

NRC review ↓ Unit 6 [SR Radio Dr]

(R) distorted globe = ON enhancement

(+) = thickness is less as compared to other ON

(L) WNL

[enhancement few mm anterior to chiasm]

As compared to previous scan, mass has decreased significantly

- No intracranial extension noted

कृपया इस कार्ड को सुरक्षित रखें तथा अस्पताल में दिखाने के समय हर वक्त साथ लायें।

Kindly keep this Card safely and bring it on your follow-up visits.

1. धूम्रपान निषेध 2. कूड़ा कर्कट केवल कूड़ेदान में ही डालें 3. धुकिये नहीं

1. No Smoking

2. Use Dustbin

3. No Spitting



Patient Name: BABY ANUSHKA	Center Name: A S HEALTH SQUARE
Age / Sex: 4 Y / F	Referred By: A.I.I.M.S.
Patient ID: 37358	Date: 29/06/2024

CEMRI BRAIN WITH ORBIT

MR IMAGING OF BILATERAL ORBITAL REGION WAS PERFORMED ON A 1.5 T MR SYSTEM USING STIR, T1W AND T2W SECTIONS IN AXIAL AND CORONAL PLANES AND CORRELATED WITH T2W SAGITTAL OBLIQUE IMAGES. ADDITIONAL AXIAL T2 & FLAIR IMAGES OF BRAIN WERE OBTAINED. THE POST CONTRAST STUDY WAS PERFORMED AFTER I.V. INJECTION OF GADOLINIUM

ORBIT:

Right eyeball is shrunken with T2W hypointensity seen with hemorrhagic contents.

Right optic nerve is atrophic.

Left globe appear normal in MR morphology. No obvious vitreous hemorrhage and retinal detachment is seen on left side. Left optic nerve shows normal signal intensity and contours.

Left extra-ocular muscles, intraconal and extraconal spaces show normal MR morphology with no evidence of any obvious focal signal alteration or collection apparent at present on the available MR images.

Retro-ocular space and fat planes are preserved on left side. Optic chiasma appears normal in contours and signal intensity on left side.

BRAIN:

Cerebral parenchyma show normal MR morphology with maintained grey-white matter differentiation. No focal lesion is seen. No midline shift seen. Corpus callosum is normal. No evidence of restricted diffusion noted.

The basal ganglia, thalami and internal capsules appear normal.

The mid-brain, pons and medulla appear normal. The cerebellum appears normal.

The ventricular system appears normal. The sulci, fissures & basal cisterns appear normal.

The pituitary gland and bilateral parasellar regions appear normal.

IMPRESSION: MR FINDINGS REVEAL SHRUNKEN RIGHT EYEBALL WITH ALTERED SIGNAL INTENSITY WITH HEMORRHAGIC CONTENTS WITH ATROPHIC RIGHT OPTIC NERVE.

Please correlate clinically

Dr. SANDEEP DUA
HOD Radiology
MBBS, MD, DMC, 31131

The above report is a professional opinion and needs to be correlated with clinical history and other relevant investigation for final diagnosis. If no results are alarming or unexpected may be due to typographic errors, hence please contact within 7 days.

29/4/24

Plan

- C#3 as overleaf → 1/5/24
- Post chemo supportive care as overleaf
- FU on 20/5/24 = C#4/LM/RF1
- T. Buscopan (1/2 tab) sos *Am*

DAYCARE MEDICAL
 MEDICAL ONCOLOGY
 AIMS
 Date: 29/4/24
 Time: 7:30 AM

Dr. Astha Goel / Dr. Astha Goel
 Senior Resident / Senior Resident
 Medical Oncology / Medical Oncology
 All India Institute of Medical Sciences / All India Institute of Medical Sciences
 Dr. Sarabjit Singh / Dr. Sarabjit Singh
 Senior Resident / Senior Resident
 All India Institute of Medical Sciences / All India Institute of Medical Sciences

DATE 22/5/24
 TIME 11:30 AM
 DC-1
 22/5/24

21/5/24

- Go for C#3 as overleaf
 ↳ [22/5/24]
- Post chemo supp care as overleaf

12/6/24

C#4 as overleaf → 13/6/24

CEMRI Main = relit

FU on 3/7/24 = C#5/LM/RF1 + cases

Optimal FU → for resection

Am
 Dr. Astha Goel / Dr. Astha Goel
 Senior Resident / Senior Resident
 Medical Oncology / Medical Oncology
 All India Institute of Medical Sciences / All India Institute of Medical Sciences

DAYCARE MEDICAL
 MEDICAL ONCOLOGY
 AIMS
 Date: 12/6/24
 Time: 7:30 AM

wt. 11.5 kg

F/U [10/6/24] = C#6

Shubhash
 Dr. Shubhash
 Senior Resident (DM)
 Medical Oncology
 AIMS, New Delhi

दिनांक - Date

उपचार - Treatment

18/3/24

Repeat usg today

18/3/24

(R) Mtd to mod. amplitude spikes filling entire vc s/o? VH/VS
a few high spikes s/o calcification

CPD Dr. Lomi

- Syb. amoxicillin 15ml OD ABF

- Syb. Augmentin [228/5ml] 4ml TDS

- Syb Digene 2ml BD

(R) Syb Belmotel (2)

Elb HA 2% (2)

Elb Predacetate (6)

Elb Mycin (3)

DDA for (R) evaluation & evaluation on CPD/W Dr. Anglu

Ward 4A CPD
down

27/3/24
CPD/W Dr. Lomi Sr
Adv - Oculoplasty opinion

Consultant opinion OT 5th floor
28/3/24 9am

6/4/24

Ward 4A 8am

Ward 4A for CP

नेत्र ईश्वरीय सर्वश्रेष्ठ उपहार है जिनका मनुष्य जीवन में दान करना परमश्रेष्ठ है।

इनकी पूर्ण रक्षा कीजिए ताकि ये आपकी रक्षा कर सकें।

Eyes are God's most precious gift to man kind and eye donation is the most noble deed.

Take full care of them so that they can take care of you.

29/4/24

Plan

- CA & no overleaf → 1/5/24
- Post chemo supportive care no overleaf
- FU on 20/5/24 = CBX/LM/RP1

Jan


 Dr AASTHA GOEL
 MCh, Surgical Oncology
 Department of Surgical Oncology
 All India Institute of Medical Sciences
 Dr BRAHMACHARI (Surgical Oncology) Room No. 110029
 All India Institute of Medical Sciences
 Anand Nagar, New Delhi-29

JAN LAKSHYA TRUST

ब० रो० वि० कार्ड
O.P.D. Card



अनुभाग व दिन
Section and Day **VI**
बुधवार व शनिवार
Wednesday & Saturday

कमरा नंबर
Cabin No.

डा० राजेन्द्र प्रसाद नेत्र विज्ञान केन्द्र
अ० मा० आयु० सं०, नई दिल्ली - 110029

Dr. Rajendra Prasad Centre for Ophthalmic Sciences
A.I.I.M.S., New Delhi-110029

यू०एच०आई०डी० संख्या
UHID No. 107270663

आचार्य राधिका टंडन का एकक
Prof. Radhika Tandon's Unit

रोगी का नाम Name of the Patient	पुत्र/पुत्री/पत्नी S/D/W	लिंग Sex	आयु Age	पता Address
Amushika		F	4	

दिनांक DATE	निदान DIAGNOSIS
----------------	--------------------

उपचार Treatment

18/3/24

c/s/B Radiology SR

RE - Embargo
T2 hyper/hypointense mass (blood-flow level)
T2 hyperintense in supranuclear region
(well defined, lobulated)
no post contrast enhancement
periorbital thickening of soft tissue (T2 hyperintensity)
retro-orbital fat standing (+)
fo? paraneoplastic.

JANAKI SINGH TRUST

142
old case
class
2pm

कृपया इस कार्ड को सुरक्षित रखें तथा अस्पताल में दिखाने के समय हर वक्त साथ लायें।

Kindly keep this Card safely and bring it on your follow-up visits.

107276663

ब. रो. वि. कार्ड
O.P.D. Card



अनुभाग व दिन
Section and Day VI
बुधवार व शनिवार
Wednesday & Saturday

कमरा नंबर
Cabin No.

डा. राजेन्द्र प्रसाद नेत्र विज्ञान केंद्र
अ. भा. आयु. सं., नई दिल्ली - 110029

Dr. Rajendra Prasad Centre for Ophthalmic Sciences
A.I.I.M.S., New Delhi-110029

यू.एच.आई.डी. संख्या
UHID No.

आचार्य राधिका टंडन का एकक
Prof. Radhika Tandon's Unit

रोगी का नाम Name of the Patient	पुत्र/पुत्री/पत्नी S/D/W	लिंग Sex	आयु Age	पता Address
Anushka				

दिनांक DATE	निदान DIAGNOSIS	उपचार Treatment
	(R) Retrolental	(L) Grp A-B
		Multifocal

28/3/2024

Adv -> CEMRI - Orbit & Brain

Adv: ~~OPAS~~ ~~SPISA~~ Ref'd to Dr. Ramesh B. Khosla

→ FRCH Mon/Thu

for Rystereon

Parents seen

1/5/24

Rev. & Film on Tue

Ref'd to Dr. Ramesh B. Khosla
Ped
Acare

कृपया इस कार्ड को सुरक्षित रखें तथा अस्पताल में दिखाने के समय हर वक्त साथ लायें।

Kindly keep this Card safely and bring it on your follow-up visits.

1. धूम्रपान/निषेध No Smoking
2. कूड़ा कंस्टेन बिन कूड़ेदान में ही डालें Use Dustbin
3. थूकिये नहीं No Spitting

ब० रो० वि० कार्ड
O.P.D. Card



अनुभाग व दिन
Section and Day VI
बुधवार व शनिवार
Wednesday & Saturday

कमरा नंबर
Cabin No.

डा० राजेन्द्र प्रसाद नेत्र विज्ञान केन्द्र
अ० भा० आयु० सं०, नई दिल्ली - 110029

Dr. Rajendra Prasad Centre for Ophthalmic Sciences
A.I.I.M.S., New Delhi-110029

यू०एच०आई०डी० नंबर
UHID No. 18127663

आचार्य राधिका टंडन का एकक
Prof. Radhika Tandon's Unit

दिनांक DATE	निदान DIAGNOSIS	रोगी का नाम Name of the Patient	पुत्र/पुत्री/पत्नी S/D/W	लिंग Sex	आयु Age	पता Address
		L. Mishra		M	47	

उपचार Treatment

5/2/24

Clbs Dr. N. Lami

(R) USG - mod. myxomatous spikes throughout VC
E few spikes of calcification

↓
f. 2% 2%. (3)
(R) 2% Prednisolone (4)
★ 2% Mycin (3)

Review after 2 weeks for repeat USG

कृपया इस कार्ड को सुरक्षित रखें तथा अस्पताल में दिखाने के समय हर वक्त साथ लायें।

Kindly keep this Card safely and bring it on your follow-up visits

Findings < | Child extremely uncooperative

(E) USG → VII/VI @

• Dist. tube - ? calculation
? old RD

Adv: NFO currently inadequate

Av in #62 tomorrow at 9am - adequate NFO for
(26/01/24)

(R) Esophagus draining IVP. LGA.
? plate exploration

T. PCM 500mg 1/2 tab 600 for min.

26/1/24

1/0 trauma - to eye 1 - smooth back
→ currently patient is having active VRTI

Advise → finally optimize active VRTI
→ Get one pediatric medicine reference done 1/0 active
VRTI and start E medication,
→ It can be taken for 6x after optimization.

Adv:

- MDU clearance & VRTI optimization
- Flap in #62 open VRTI resolves.

Handwritten signature/initials

Handwritten notes

27/01/24

C/S/B SR unit VI today in casualty

V_n - PL - re
- Retina opium

(R)

- Tab. Diamox 1/8 tab $\frac{Adv: - NO intervention in$
TDS $\frac{5000}{5 days}$ i/v/o $\frac{PR and USG showing$
- E/d HA 2/ BD 00 Old RD.
- E/d Paracetamol (4) Flux 2 days in OPD by
- E/d Iobol 0.5/ BD 00

दिनांक - Date

4y / F

उपचार - Treatment

~~PP~~

do redness in (RE) x 1.5 months
peri-orbital swelling (+)

→ No H/O
Leuko (Kosh)

→ No H/O fever

No family history

Room (142)

RB Clinic 2pm

USG (RB) to look
for calcifications

JAN LAKSHYA TRUST

नेत्र ईश्वरीय सर्वश्रेष्ठ उपहार है जिनका मनुष्य जीवन में दान करना परमश्रेष्ठ है।

इनकी पूर्ण रक्षा कीजिए ताकि ये आपकी रक्षा कर सकें।

Eyes are God's most precious gift to man kind and eye donation is the most noble deed.

Take full care of them so that they can take care of you.

दिनांक - Date

उपचार - Treatment

Parent screening done → (B/E) Disc & Macula
Healthy

No obvious peripheral
treatable lesion

CE-MRI [Brain + orbit] T₁ & T₂; Fat suppressed;
Imm cuts passing through optic nerve
and pineal gland in Axial, coronal &
sagittal plane

NRC 53 (Wednesday) @ 10:00 AM.
MRI films.

→ Refer to Paeds
emergency for
pain management

T. Tramadol 50 1/2 tab SOS

4p Nifedipine 5ml SOS

4p PCN (250/5) 5ml SOS

Pls register in pain & palliative medicine.

नेत्र ईश्वरीय सर्वश्रेष्ठ उपहार है जिनका मनुष्य जीवन में दान करना परमश्रेष्ठ है।

इनकी पूर्ण रक्षा कीजिए ताकि ये आपकी रक्षा कर सकें।

ward 4A

Adv: -

- C/S/B Dr. Lomi
 - Continue same medications
 CECT orbit + brain (to look for
 intracocular calcification); please
 provide orbit dedicated ~~scan~~ sections

①

- Eld HA 2/1 BD

- Eld Pred 4T/D

- Eld mycin TDS 000

Syp. Augmentin (228 mg / 5ml)

3.5ml TDS 000

x 7 days

- Syp. digne 6ml BD 000

Flu reports on

Monday = MRI

CT scans
for repeat NRCat 10 am.in ward 4A

नेत्र ईश्वरीय सर्वश्रेष्ठ उपहार है जिनका मनुष्य जीवन में दान करना परमश्रेष्ठ है।

इनकी पूर्ण रक्षा कीजिए ताकि ये आपकी रक्षा कर सकें।

Eyes are God's most precious gift to man kind and eye donation is the most noble deed.


Take full care of them so that they can take care of you.

दिनांक - Date

उपचार - Treatment

optic nerve & pineal gland (to r/o
RB)

AV & MRI films on Monday
(29/01/24) at 10 am in Ward 4A



JAN LAKSHYA TRUST

नेत्र ईश्वरीय सर्वश्रेष्ठ उपहार है जिनका मनुष्य जीवन में दान करना परमश्रेष्ठ है।

इनकी पूर्ण रक्षा कीजिए ताकि ये आपकी रक्षा कर सकें।

Eyes are God's most precious gift to man kind and eye donation is the most noble deed.

Take full care of them so that they can take care of you.

ब० रो० वि० कार्ड
O.P.D. Card



अनुभाग व दिन
Section and Day **VI**
बुधवार व शनिवार
Wednesday & Saturday

कमरा नंबर
Cabin No.

डा० राजेन्द्र प्रसाद नेत्र विज्ञान केन्द्र
अ० भा० आयु० सं०, नई दिल्ली - 110029

Dr. Rajendra Prasad Centre for Ophthalmic Sciences
A.I.I.M.S., New Delhi-110029

यू०एच०आई०डी० संख्या
UHID No. 10727663

आचार्य राधिका टंडन का एकक
Prof. Radhika Tandon's Unit

रोगी का नाम Name of the Patient	पुत्र/पुत्री/पत्नी S/DW	लिंग Sex	आयु Age	पता Address
Anneeka	4/F			

दिनांक DATE	निदान DIAGNOSIS
----------------	--------------------

उपचार Treatment

C/S/B SR Unit II Dr. Somya

(R) USG → R eye mass
= speckles of calcification
S/O RB

No intervention from Retinal
side. TO r/o RB.

C/S/B SR Unit VI

- CEMRI orbit + brain fat suppressed,
gad enhanced sagittal, coronal & axial
sections 2mm cuts passing through

कृपया इस कार्ड को सुरक्षित रखें तथा अस्पताल में दिखाने के समय हर वक़्त साथ लायें।

Kindly keep this Card safely and bring it on your follow-up visits.

to Room 143, 2:00pm
for consultant opinion

Register for consult 7/prec

for Ocular Onc
- TODAY

c/s/b Dr. N. Lami

? Post traumatic inflammation

Adv. of

(R) E/d Predacetate (4) 0000
E/d HA 2-1. (4) 0000
E/d Tobet 0.5-1. (2) 00

R/v after 1 week / SOS in Ocular oncology
clinic

05/02/24

(R) USG - mod. amplit

Spikes throughout the
vitres c
few specks of
calcificat

(L) USG - Anecdot, c

नेत्र ईश्वरीय सर्वश्रेष्ठ उपहार है जिनका मनुष्य जीवन में दान करना परमश्रेष्ठ है।

इनकी पूर्ण रक्षा कीजिए ताकि ये आपकी रक्षा कर सकें।

Eyes are God's most precious gift to man kind and eye donation is the most noble deed.

Take full care of them so that they can take care of you.

ब० रो० वि० कार्ड

दृष्टि

अनुभाग व दिन
Section and Day VI
बुधवार व शनिवार
Wednesday & Saturday

कमरा नंबर
Cabin No.

R. P. Centre (Eye Centre)

UHID: 10726663
Dept No: 20240050010758
Clinic No.: 2024 00 28
ANUSHKA
D-O SHALESH

Date: 14/03/24
Ocular oncology Dr. SR
Ocular Oncology T42B
Unit VI
Room No.: 142

Address: VILLICHARA OULABLE
ALLIYASHI UTIAR TRAPPEER
DINDIGUL



एकक
Unit

आयु
Age

पता
Address

दिनांक
DATE

निदान
DIAGNOSIS

उपचार Treatment

eye/B old oncology clinic.

flu/clo ? Post traumatic inflammation

Mod. amplitude spikes
filling VC

Patient did not
come for NRC
@ 10AM

To come on 18/03/24, 10am, W for NRC

कृपया इस कार्ड को सुरक्षित रखें तथा अस्पताल में दिखाने के समय हर वक्त साथ लायें।

Kindly keep this Card safely and bring it on your follow-up visits.

- घूमपान निषेध 1. No Smoking
- कूड़ा कर्कट केवल कूड़ेदान में ही डालें 2. Use Dustbin
- थूकिये नहीं 3. No Spitting

ब० रो० वि० कार्ड
O.P.D. Card

दृष्टि



अनुभाग व दिन
Section and Day VI
बुधवार व शनिवार
Wednesday & Saturday

कमरा नंबर
Cabin No.

R. P. Centre (Eye Centre)

UHID: 10274463
Dept. No.: 20240050010758
Clinic. No.: 2024/00/28
ANUSHKA
D.O. SHALESH

Date: 19/02/2024 General 70

Ocular oncology - Dr. SR
Ocular Oncology 142B.

Room No.: 142

ADDRESS: VILL-CHARA GULABLI DISTT-UNNAO, UTTAR PRADESH, INDIA



म का एकक
andon's Unit

म आयु पता
EX Age Address

दिनांक
DATE

निदान
DIAGNOSIS

उपचार Treatment

cl/s/in old eye clinic

Leucocoria 1 month? Pseudophakia
H/O Trauma to (R) 2 months back

o/e (R) Congestive (L) WNL

Iridodiolysis

Miotics
Kerat

AC - shallow

13/2/24

VA

UR (du rft mg (R))

(R) Use

diffuse
Speckles in VC
few speck
of ~~calcification~~ calcification
collection of fluid behind
globe noted.

कृपया इस कार्ड को सुरक्षित रखें तथा अस्पताल में दिखाने के समय हर वक्त साथ लायें।

Kindly keep this Card safely and bring it on your follow-up visits.

- ADU
- (RE) [
- 2/d HA 2% (3)
 - 2/d predacetate (4)
 - 2/d mycosta (3)
- Symp Augmentin (222mg/5ml) 3.5ml TDS x 7 days
- Symp. digene 6ml BD 0 0 0.
- Symp. melastomum OD.
- R/U after 1 week for repeat USG.
 In R. eye: (H2B) 2pm. (Mon/med)

नेत्र ईश्वरीय सर्वश्रेष्ठ उपहार है जिनका मनुष्य जीवन में दान करना परमश्रेष्ठ है।

इनकी पूर्ण रक्षा कीजिए ताकि ये आपकी रक्षा कर सकें।

Eyes are God's most precious gift to man kind and eye donation is the most noble deed.

Take full care of them so that they can take care of you.